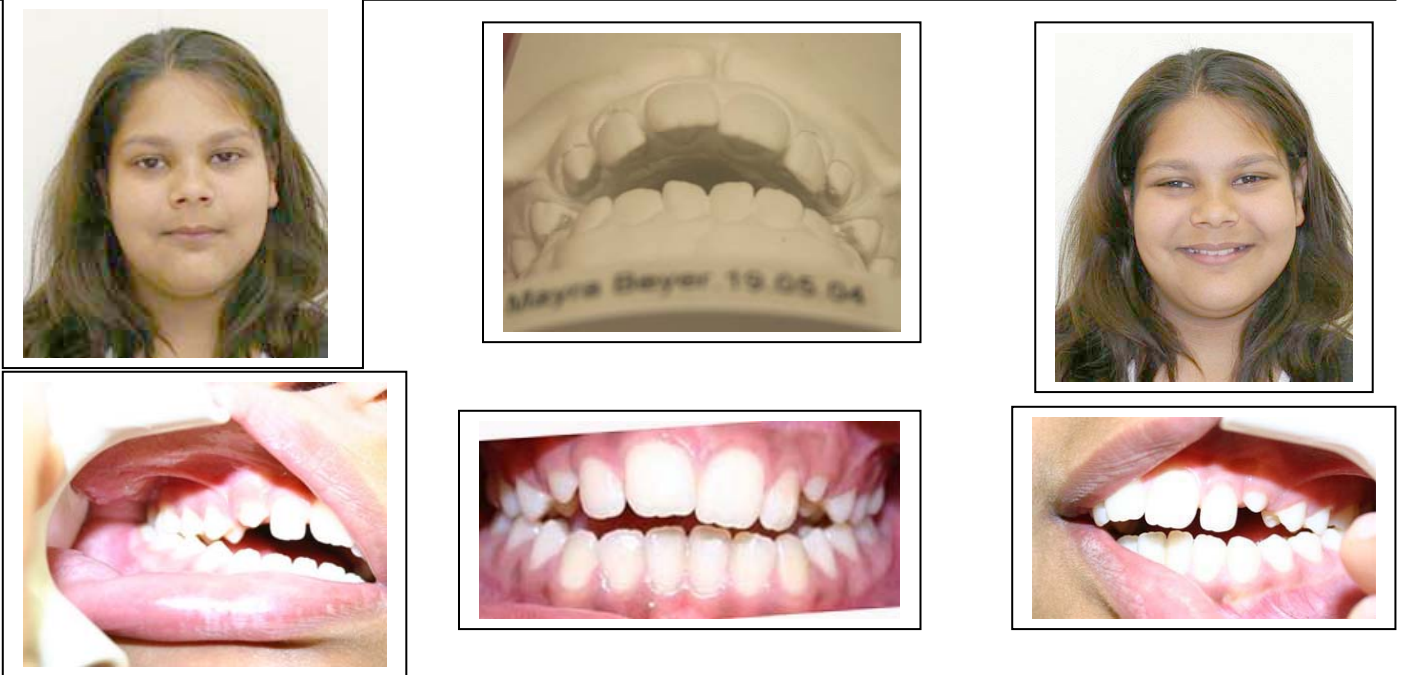

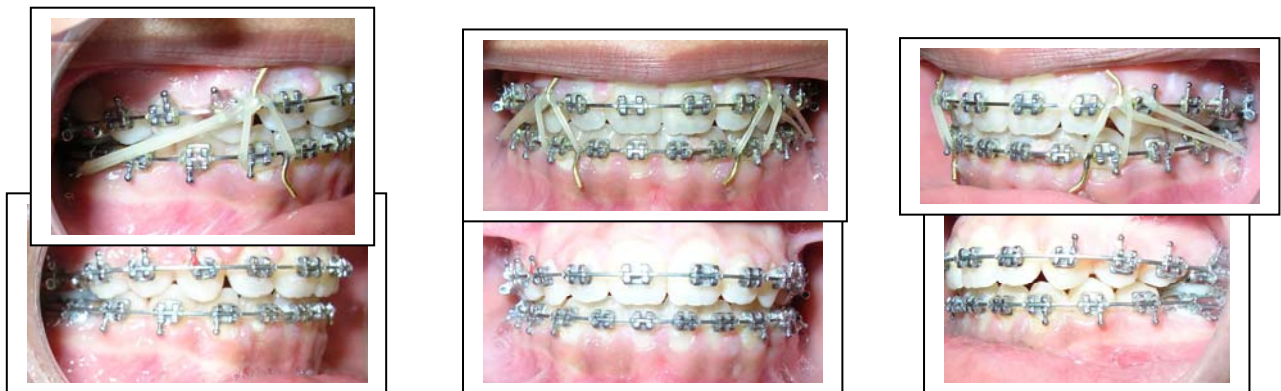
Dr. Larry Brown's system of "Esthetic Orthodontics" is used in these early mixed-dentition, non-extraction cases. This system of *Esthetic Diagnosis and Treatment Mechanics*, combined with the Straight Wire Appliance (SWA) is used as a "fixed functional appliance" in order help eliminate Dysfunctional Habits and then to enact "Growth Modification" so as to *change the face*.

Case: Anterior and posterior open-bite, severe dysfunctional soft tissue habits, CLII overjet of 10mm
Non-extraction orthodontic therapy combined with functional-habit therapy

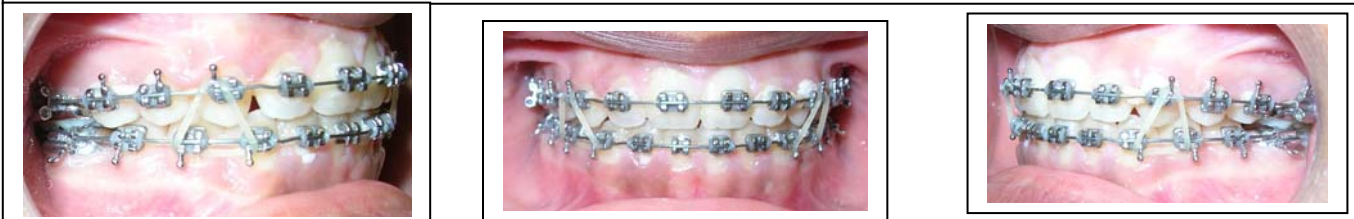
Beginning

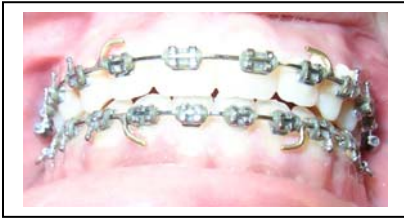



9th months - elastic therapy; dysfunctional habits are reduced

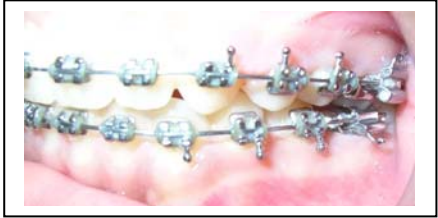
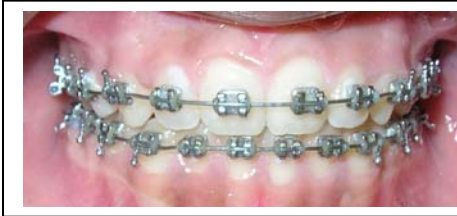
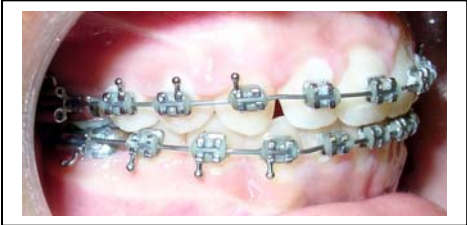15th month -----begin finishing MAX : incisor segment ---- "step-down bends" MAND: "step-up bends"





16th month – after 1 month of step-down, step-up bends



6 months after bracket removal

