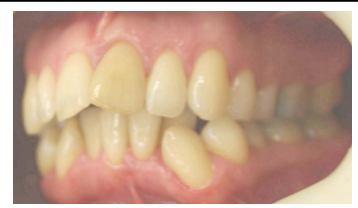
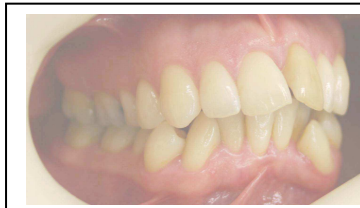
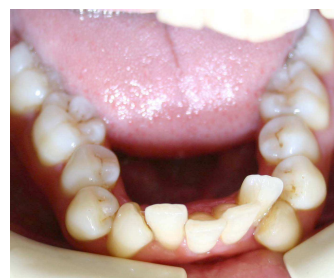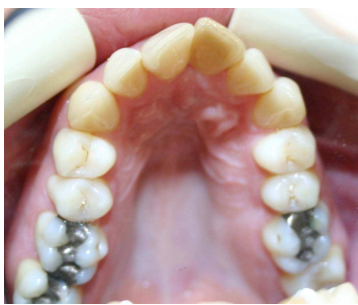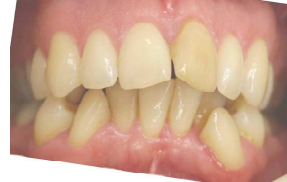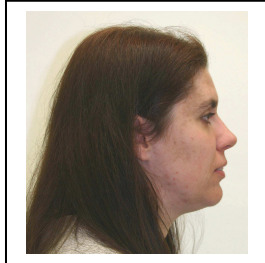

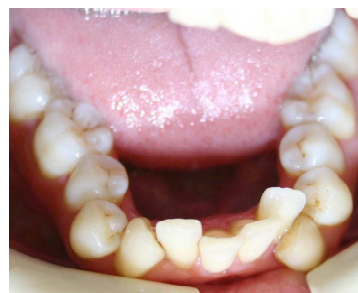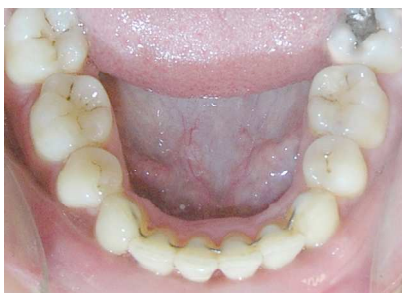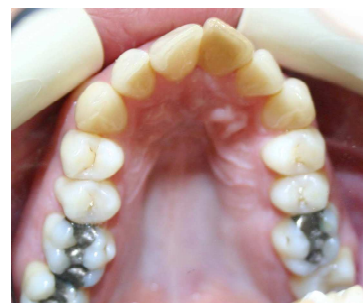


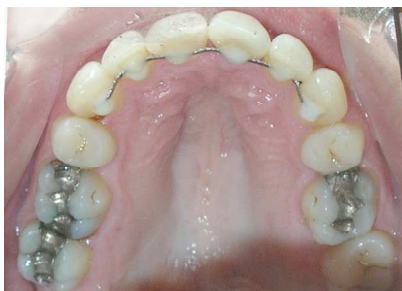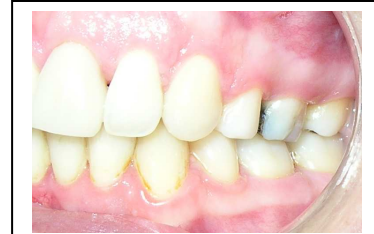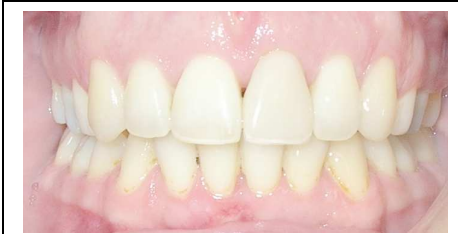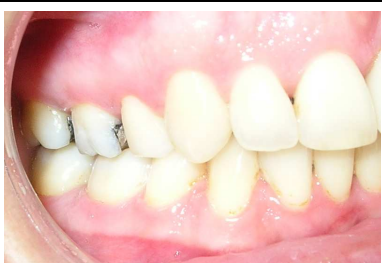**Adult female: Severe crowding with protrusion; CLII skeletal/Dental; Vertical maxillary excess; lip incompetence; maxillary prognathism; narrow collapsed arch forms.
4 premolar extraction with maximum anchorage mechanics to correct the CLII Dental, to camouflage the CLII skeletal disparity, to reduce the protrusion and create lip competence.**

Beginning



Final: CLI occlusion; # 21 was restored with a porcelain veneer



Retention: Maxillary and mandibular fixed lingual “dead soft wires” and QCM removable retainers

