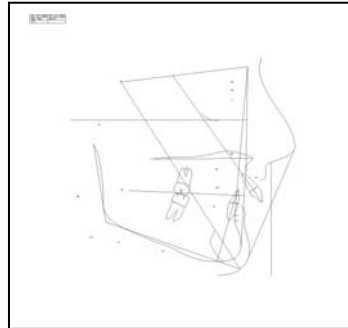
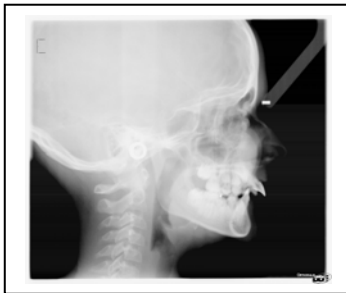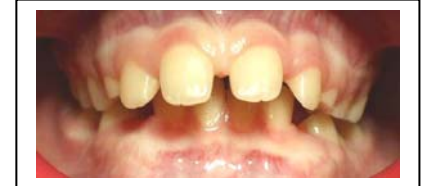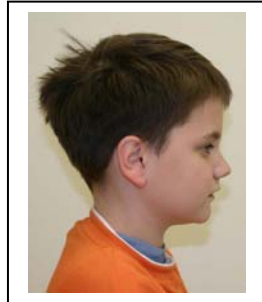


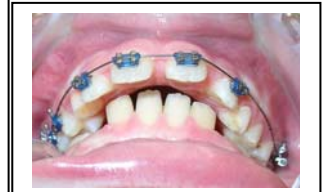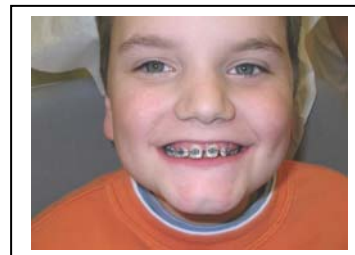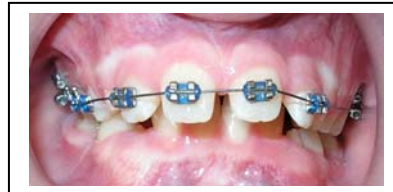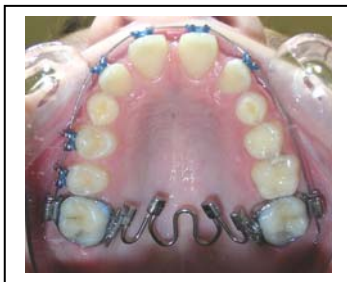Dr. Larry Brown's system of "Esthetic Orthodontics" is used in these early mixed-dentition, non-extraction cases. This system of *Esthetic Diagnosis and Treatment Mechanics*, combined with the Straight Wire Appliance (SWA) is used as a "fixed functional appliance" in order help eliminate Dysfunctional Habits and then to enact "Growth Modification" so as to *change the face*.

Case: Boy, Age 12, Dental age 11.5, CLII div I Overjet = 15mm Overbite = 6mm
Soft tissue dysfunctions following thumb sucking habit.
Use of SWA, NiTi Transpalatal appliance, wires as a "fixed functional appliance"



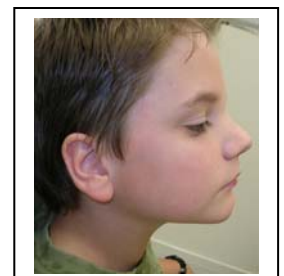
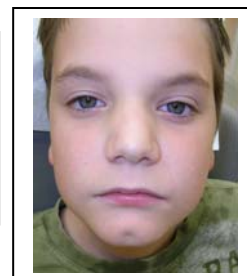
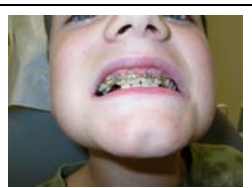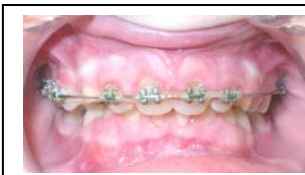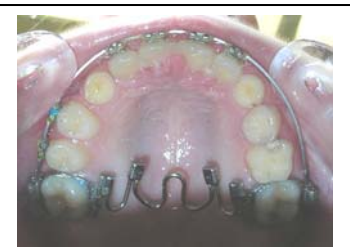Beginning:

MAX: 2x5 with Heat activated NiTi transpalatal appliance, 16 HA NiTi wire with molar bend-backs.



After 2.5 months:

MAX: Lip-closure established automatically with the dental changes; place 17x25 NiTi "RCS" wire.



Bite opening while waiting for the teeth to erupt; over-jet reduced.

