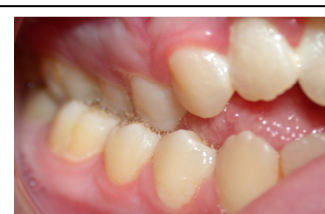
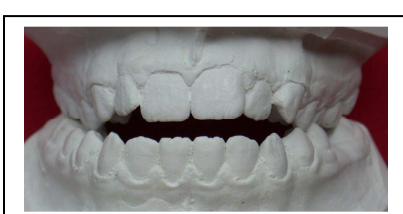
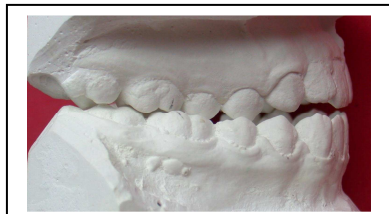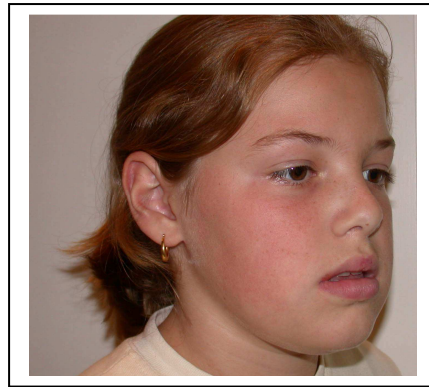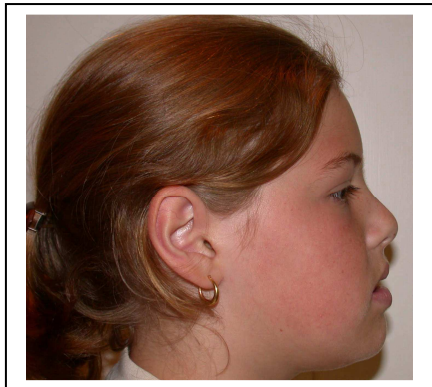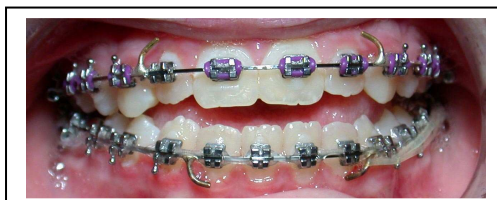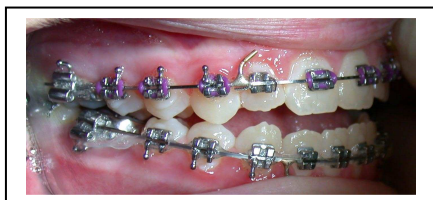Dr. Larry Brown's system of "Esthetic Orthodontics" is used in these early mixed-dentition, non-extraction cases. This system of *Esthetic Diagnosis and Treatment Mechanics*, combined with the Straight Wire Appliance (SWA) is used as a "fixed functional appliance" in order help eliminate Dysfunctional Habits and then to enact "Growth Modification" so as to *change the face*.

Case: CLIII skeletal with Anterior open bite, tongue thrust; case requires extraction of 2 teeth on mandible; this case is treated similar to most cases using only the Brackets, wires and intraoral elastics.

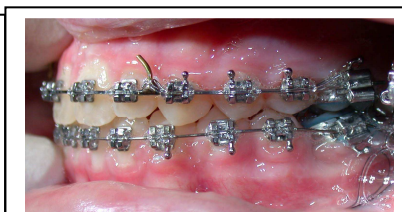
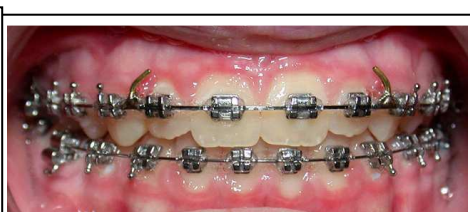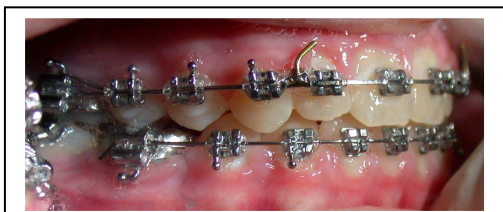

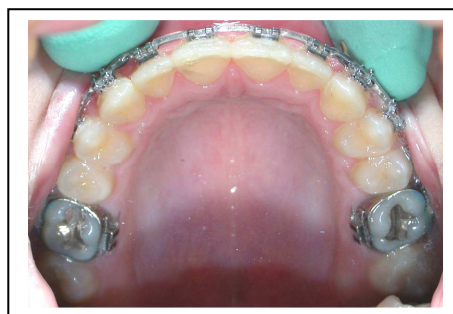Beginning



6th month



12 month: End of 1st Phase – the dysfunctional habits are eliminated, a more ideal occlusion is established and the facial pattern is changed.



Final

