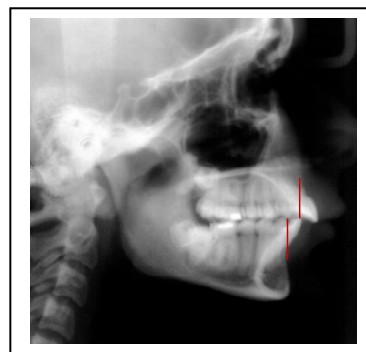
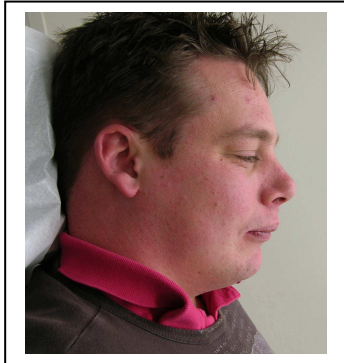
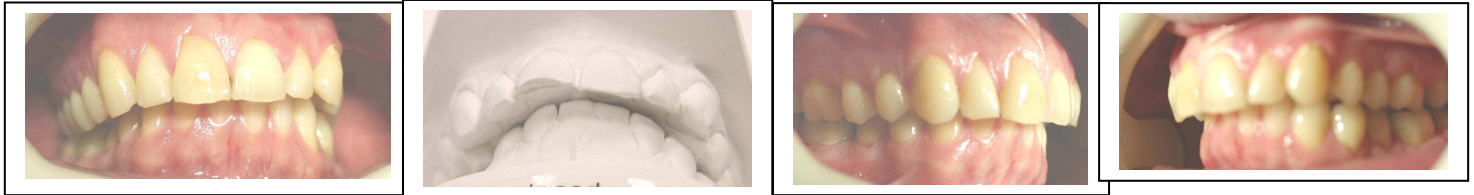
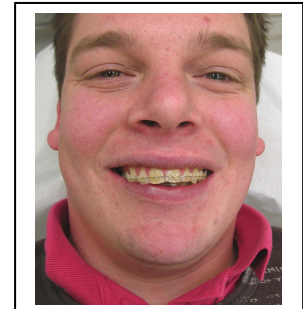
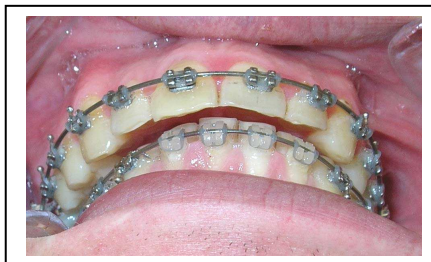
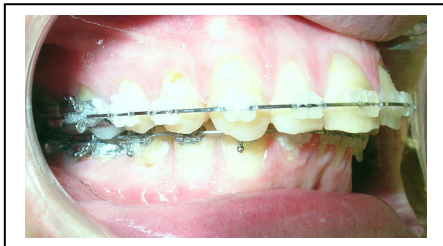Surgical Case: Adult Male. Full CLII div I with 8mm overjet and a deep bite with deep Curve of Spee. CLII skeletal with Wits of +8. Maxillary arch is skeletally normal and the lip profile position is good. Mandibular arch is skeletally retrognathic (~8mm). Esthetically the mandibular body length looks too short and retruded. Treatment Plan: Orthodontics (using the SWA) combined with a **BSSO surgical procedure** "**mandibular advancement**" by the maxillo-facial surgeon.



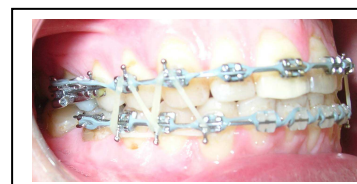
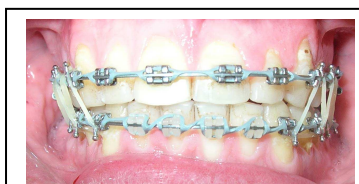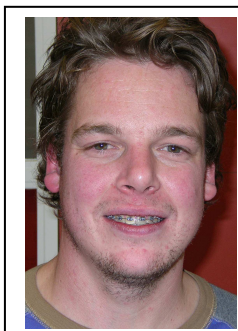
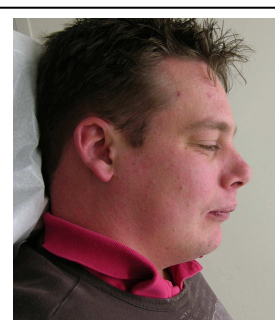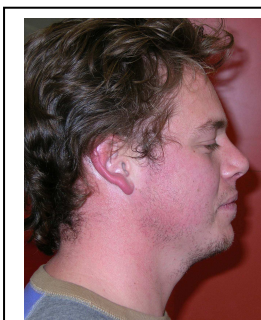
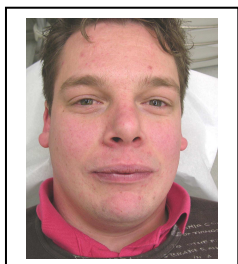
6th month: All teeth are bracketed/banded. The final stages of leveling with the SWA.



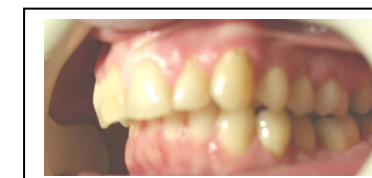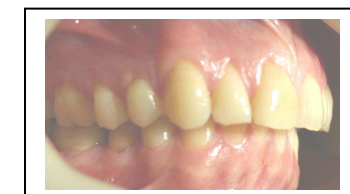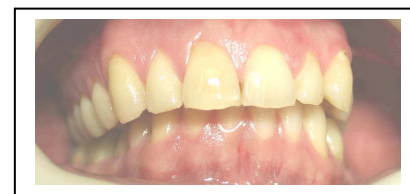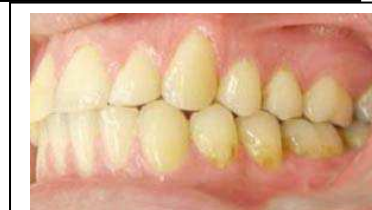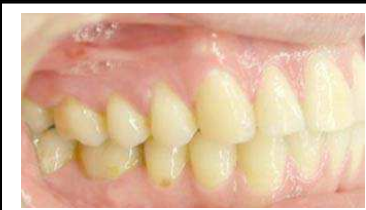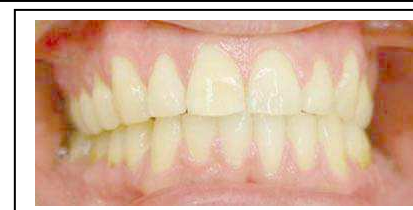10th month: BSSO surgical procedure - mandibular advancement

14th month: 3 months after the BSSO surgical mandibular advancement.

Final finishings – 19x25 HA NiTi wires, segmented and 4mm delta elastics to settle in the occlusion. Before and after photos.



Before and after photos



Retention: Fixed lingual wires from 3 to 3 plus removable retainers.

